

A Step-by-Step Discussion about fMRI with Other Methods

Soma Datta¹, Dr. Samir Kumar Bandyopadhyay²

¹ Department of Computer Science and Engineering, West Bengal University of Technology, Kolkata, India

² Vice Chancellor, West Bengal University of Technology, Kolkata, India

ABSTRACT: Since twenty years ago, functional magnetic resonance imaging (fMRI) has been used in numerous studies neural effects of human cognition. On that time fMRI was important in context of clinical application as well as pharmacological application. Now the scope of fMRI is not restricted only in clinical or pathological aspects; now it is also used in crime detection and other works. So a lot of automation in terms of image processing is required to minimize computation and decision making time. As a result there is an opening for computer science professional, but they have no prior knowledge regarding fMRI. This document gives a clear idea about fMRI for those who are neither radiologist nor neurologist but interested in fMRI. This document also discusses about fMRI image database and Data format for image processing. .

KEYWORDS: Blood-oxygen-level-dependent, Computed tomography, Deoxyhemoglobin, Electroencephalography, fMRI

I. INTRODUCTION

Functional magnetic resonance imaging or functional MRI (fMRI) is an MRI procedure that measures brain activity by detecting associated changes in blood flow. This technique relies on the fact that cerebral blood flow and neuronal activation are coupled. When an area of the brain is in use, blood flow to that region also increases. The primary form of fMRI uses the blood-oxygen-level-dependent (BOLD) [1] [2] [3] contrast, discovered by Seiji Ogawa in the year of 1990. fMRI is based on the idea that blood carrying oxygen from the lungs behaves differently in a magnetic field than blood that has already released its oxygen to the cells. In other words, oxygen-rich blood and oxygen-poor blood have a different magnetic resonance. Scientists know that more active areas of the brain receive more oxygenated i.e., deoxy-hemoglobin concentrated [4] [5] [6] [7] [8] [9] blood. The fMRI picks up this increased blood flow to pinpoint greater activity. The measurement of blood flow, blood volume and oxygen use is called the blood-oxygen-level-dependent (BOLD) signal. The central thrust behind fMRI was to extend MRI to capture functional changes in the brain caused by neuronal activity. Both conventional and functional MRI use a powerful magnet and radio waves to produce images of the brain. Conventional MRI images show beautifully detailed anatomy, and are an essential part of modern medicine. In fMRI, the same scanner is optimized to detect small changes in blood flow in the brain in response to scientifically designed stimuli. In principle, fMRI can be used to observe the activation of brain structures in response to almost any kind of brief stimulation, ranging from sounds, to visual images, to gentle touching of the skin. Currently, fMRI is being used across the world as a powerful neuroscientific research tool to study how the brain works, although some medical applications are being discovered as well. Fig 1 shows BOLD design fMRI experiment showing an overlapping Paradigm consisting of visual and auditory stimulation epoch. The auditory stimulus consisted of recorded speaking Voices for 45 seconds alternated with 45 seconds of rest. A combined Analysis was applied to reveal the visual (yellow–red) and Auditory (green–blue) processing areas of the brain.

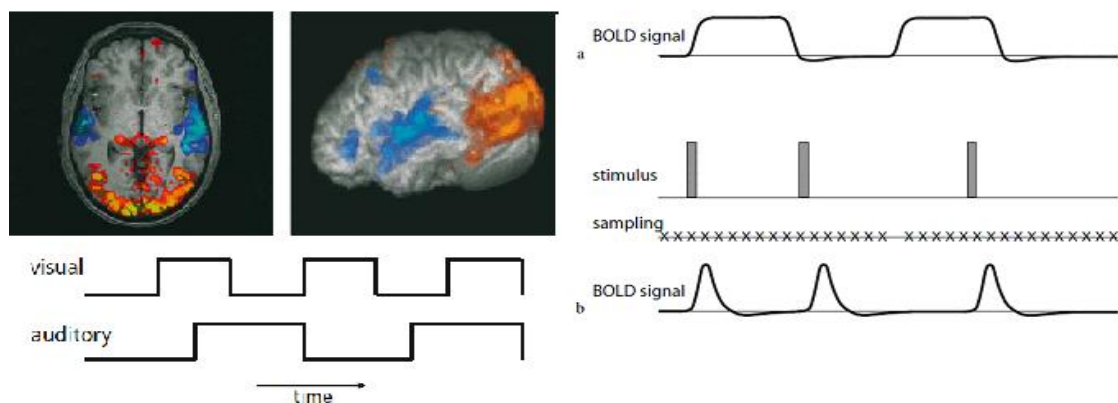


Fig 1 Shows BOLD design fMRI experiment along with fMRI paradigm (a), and an eventrelated fMRI paradigm (b)..

II. DETAIL OF fMRI

fMRI stands for functional magnetic resonance imaging. In order to understand how it works, it is first necessary to understand conventional magnetic resonance imaging, or MRI. MRI is a technique for producing astonishingly detailed images of the brain or other bodily structures (see Fig 1). These images demonstrate the anatomy of the subject's brain at high resolution, and are used in virtually all modern hospitals to diagnose a wide variety of brain disorders, including brain tumors, multiple sclerosis, and stroke. MRI scanning uses a very strong magnet and radio waves to produce these spectacular images. The subject lies on a table, with his head surrounded by a large magnet. The magnet causes some of the atoms (or, more precisely, particles inside the atoms, called protons) inside the patient's head to align with the magnetic field. A pulse of radio waves is then directed at the patient's head and some of it is absorbed by the protons, knocking them out of alignment. The protons, however, gradually realign themselves, emitting radio waves as they do. These radio waves are captured by a radio receiver and are sent to a computer, which constructs the brain image. The patient cannot sense either the magnet or the radio waves; in fact, the patient only knows the machine is working because of the noise it makes during scanning. Different parts of the brain respond to the radio waves differently, and emit slightly different radio signals depending, among other things, on the local water and fat content. The computer that receives all of the signals, therefore, is able to distinguish one brain structure from another, and produce remarkable anatomical images, such as that shown in Fig 2.

The subject is facing to the right (the nose is in the lower right), and this slice is taken straight down the middle of the brain. The blood contains iron, which is the oxygen-carrying part of hemoglobin inside red blood cells. Iron atoms cause small distortions in the magnetic field around them. Not all iron atoms do this: for the case of blood, only iron not bound to oxygen does this ("deoxyhemoglobin") [10][11][12]. fMRI is the physiological principle that whenever any part of the brain becomes active, the small blood vessels in that localized region dilate, causing more blood to rush in. The blood is presumably needed to provide extra oxygen and fuel (glucose) for the active brain cells. The result, however, is that a large amount of freshly oxygenated blood pours into any activated brain structure, reducing the amount of oxygen-free (deoxy) hemoglobin. This causes a small change in the magnetic field, and thus the MRI signal, it was shown that an MRI scanner can be used to detect this small change in the signal, and thus detect which areas of the brain have been activated. So, for example, if a patient lying in a scanner is suddenly shown a flash of light, the visual cortex in his brain will become activated, blood flow there will quickly increase, and the MRI signal will change. The result is usually displayed as a patchy area of color, representing the brain area activated, superimposed upon a conventional, high-resolution, gray-scale image of the subject's brain (Fig 3). The signal is often called a BOLD signal [13][14][15], standing for Blood Oxygen Level Dependent signal.

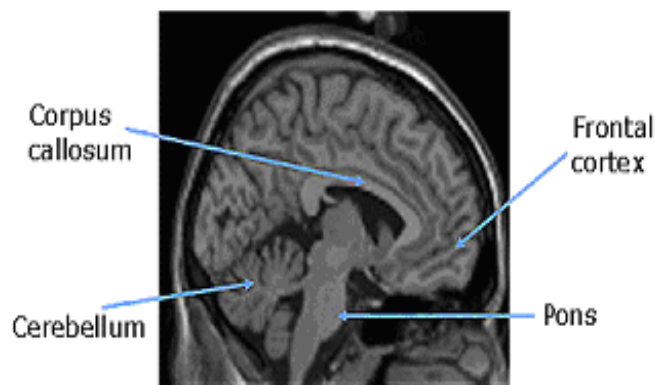


Fig 3: Conventional MRI of the human brain

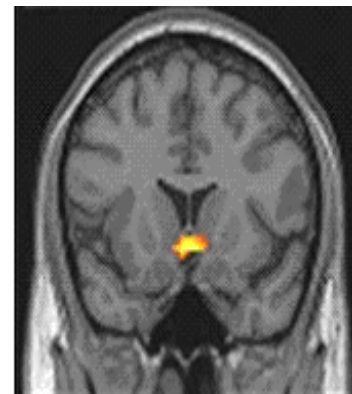


Fig 4: fMRI image

Note that the yellow-orange area indicates the part of the brain that was significantly activated during the study. This is the ventral striatum, which was activated in this case by unpredicted squirts of juice into the subject's mouth. This area of activation is shown superimposed upon a high-resolution, 'conventional' MRI scan of the subject's brain, shown in gray-scale. To orient yourself, imagine that the subject is facing you, and you are looking at a slice of his brain taken from the mid-to-frontal part of his head. Although an fMRI test [16][17][18][19][20] doesn't use radiation, its strong magnetic field and radio waves may not be recommended for certain groups of people including pregnant women, people with an internal defibrillator or pacemaker, those with artificial heart valves or limbs, people with cochlear implants, people with an infusion catheter, those with clips used on brain aneurysms, women with an intrauterine device (IUD) and people with metal pins, screws, plates or surgical staples

III. OTHER BRAIN IMAGING TECHNIQUES AND COMPARISON WITH fMRI

fMRI complements a number of other ways of looking at the brain. [21][22][23][24]

CT: Computed tomography (CT) scanning builds up a picture of the brain based on the differential absorption of X-rays. During a CT scan the subject lies on a table that slides in and out of a hollow, cylindrical apparatus. An x-ray source rides on a ring around the inside of the tube, with its beam aimed at the subjects head. After passing through the head, the beam is sampled by one of the many detectors that line the machine's circumference. Images made using x-rays depend on the absorption of the beam by the tissue it passes through. Bone and hard tissue absorb x-rays well, air and water absorb very little and soft tissue is somewhere in between. Thus, CT scans reveal the gross features of the brain but do not resolve its structure well.

PET: Positron Emission Tomography (PET) uses trace amounts of short-lived radioactive material to map functional processes in the brain. When the material undergoes radioactive decay a positron is emitted, which can be picked up by the detector. Areas of high radioactivity are associated with brain activity.

EEG: Electroencephalography (EEG) is the measurement of the electrical activity of the brain by recording from electrodes placed on the scalp. The resulting traces are known as an electroencephalogram (EEG) and represent an electrical signal from a large number of neurons. EEGs are frequently used in experimentation because the process is non-invasive to the research subject. The EEG is capable of detecting changes in electrical activity in the brain on a millisecond-level. It is one of the few techniques available that has such high temporal resolution.

MEG: Magnetoencephalography (MEG) is an imaging technique used to measure the magnetic fields produced by electrical activity in the brain via extremely sensitive devices known as SQUIDS. These measurements are commonly used in both research and clinical settings. There are many uses for the MEG, including assisting surgeons in localizing a pathology, assisting researchers in determining the function of various parts of the brain, neuron-feedback, and others.

NIRS: Near infrared spectroscopy is an optical technique for measuring blood oxygenation in the brain. It works by shining light in the near infrared part of the spectrum (700-900nm) through the skull and detecting how much the reemerging light is attenuated. How much the light is attenuated depends on blood oxygenation and thus NIRS can provide an indirect measure of brain activity.

ADVANTAGES OF fMRI

- The big advantage of fMRI is that it doesn't use radiation like X-rays, computed tomography (CT) and positron emission tomography (PET) scans. If done correctly, fMRI has virtually no risks. It can evaluate brain function safely, noninvasively and effectively.
- fMRI is easy to use, and the images it produces are very high resolution (as detailed as 1 millimeter). Also, compared to the traditional questionnaire methods of psychological evaluation, fMRI is far more objective.

DISADVANTAGES OF fMRI

- It's too expensive.
- Second, it can only capture a clear image if the person being scanned stays completely still.
- Researchers still don't completely understand how it works.
- The biggest complaint from researchers is that fMRI can only look at blood flow in the brain. It can't home in on the activities of individual nerve cells (neurons), which are critical to mental function.
- In addition, the results of an fMRI scan can be difficult to interpret.
- fMRI has often been used to show activation localized to specific regions, thus minimizing the distributed nature of processing in neural networks.
- The images produced must be interpreted carefully, since correlation does not imply causality, and brain processes are complex and often non-localized.
- fMRI has poor temporal resolution. The BOLD response peaks approximately 5 seconds after neuronal firing begins in an area. This means that it is hard to distinguish BOLD responses to different events which occur within a short time window. Careful experimental design can reduce this problem. Also, some research groups are attempting to combine fMRI signals that have relatively high spatial resolution with signals recorded with other techniques, electroencephalography (EEG) or magnetoencephalography (MEG), which have higher temporal resolution but worse spatial resolution[25][26][27][28][29][30].

IV. APPLICATION OF MRI

Magnetic resonance imaging (MRI)[31][32][33][34][35] [36]can be used to produce detailed images of almost any part of the body. MRI scans are often used to examine the brain and spinal cord, bones and joints, breasts, heart and blood vessels etc. It is also possible for an MRI scan to be used to examine other internal organs, such as the lungs or liver.

An MRI scan can produce very detailed images of the brain and spinal. This makes MRI ideal for helping to diagnose conditions that affect the brain and nervous system. For example:

Brain tumours, Dementia, Alzheimer's disease, Stroke, Parkinson's disease, Multiple sclerosis, Motor neurone disease, Brain infections like meningitis and encephalitis, Injuries to the brain or spinal cord, Bones and joints etc.

MRI scans are a very effective way of checking for damage or abnormalities to the soft tissue found in bones and joints, such as cartilage, tendons, muscles and ligaments. This means that an MRI scan can be used to help diagnose conditions that assess damage to the cartilage, tendons, muscles and ligaments in the bones and joints.

MRI scans are now often used to help diagnose breast cancer. They can provide a way of checking how much of the breast is affected by cancer, although they are not needed in all cases. MRI is also sometimes used to assess breast implants.

MRI scans can be used to produce detailed images of your heart. The images can often help detect specific problems with the heart, such as defects with the valves or chambers. MRI scans can also help assess whether a person's heart has been significantly damaged after having a heart attack.

V. APPLICATION OF fMRI

Functional MRI is a fairly new technique that is used to study the workings of the brain. A functional MRI takes repeated scans, usually one a second, rather than a single scan. The scans are used to track the movement of blood through the brain. This allows the sections of the brain that are particularly active to be identified. It also shows how brain activity responds to outside events and activities. For example, a volunteer may be asked to solve a problem or to remember a short phrase. Functional MRI can then be used to determine which parts of the brain are active during these tasks.

Functional MRI is sometimes used to help surgeons when planning complex brain surgery. Functional MRI (fMRI) [37][38][39][40] has had a major impact in cognitive neuroscience. fMRI now has a small but growing role in clinical neuroimaging, with initial applications to neurosurgical planning. There is a wider potential for clinical fMRI in applications ranging from presymptomatic diagnosis, through drug development and individualization of therapies, to understanding functional brain disorders.

Another push to use fMRI lie detection technology and also used to detect critical crime case in the world. The advanced magnetic scanning technology has been reported to determine whether someone is lying with around 90% accuracy by measuring blood flow in different parts of the brain. By tracking changes in cerebral blood flow as a subject performs a mental task, fMRI shows which brain regions "light up" when making a movement, thinking of a loved one, or telling a lie. fMRI scans of brain activity as inmates perform various tasks, including tests of moral reasoning.

Use in Early Alzheimer's Disease [10] And In Clinical Trials: Schizophrenia is a debilitating psychiatric disorder characterized by the presence of certain types of 'positive' symptoms such as delusions, hallucinations and thought disorder (Andreasen 1995). These 'positive' symptoms are usually complemented by 'negative' symptoms such as psychomotor retardation and affective flattening. fMRI has been used to investigate the neural correlates associated with both positive symptoms, negative symptoms and cognitive dysfunction over recent years.

- Examine the anatomy of the brain.
- Determine precisely which part of the brain is handling critical functions such as thought, speech, movement and sensation, which is called brain mapping.
- Monitor the growth and function of brain tumours.
- Guide the planning of surgery, radiation therapy, or other surgical treatments for the brain.
- Pre-surgical planning with functional neuroimaging has been undergoing evaluation over the past few years, particularly in cases involving resections of brain tumors and arterio-venous malformations, as well as in surgery for epilepsy. One important problem with these procedures is the collateral damage inflicted by surgery on vitally important structures and tracts in the vicinity of the lesion. By a pre-operative fMRI evaluation, it is relatively easy to visualize what cognitive, motor or sensory functions are likely to be impaired following the resection, and counsel the patient accordingly.

VI. AVAILABILITY OF fMRI DATA AND DATA FORMAT

The ultimate goal of fMRI data analysis is to detect correlations between brain activation and the task the subject performs during the scan. The BOLD signature of activation is relatively weak, however, so other sources of noise in the acquired data must be carefully controlled. This means that a series of processing steps must be performed on the acquired images before the actual statistical search for task-related activation can begin. For a typical fMRI scan, the 3D volume of the subject's head is imaged every one or two seconds, producing a few hundred to a few thousand complete images per scanning session. Some organisations put their fMRI data in the web. Like Open fMRI provides their data free of cost. They follows "Neuroimaging Informatics Technology Initiative" recommended format with file extension *.nii. [41][42][43][44][45]

VII. CONCLUSION

fMRI has a great impact not only in medical science but also in society in order to maintain the societal equilibrium. Due to urban life style and nuclear family culture young generation are facing some psychological problems. fMRI can diagnose this problem in pathological ends. So in near future the demand of computer science specialists, who are familiar with the functionality of fMRI, will increase to design the automatic diagnostic equipments which can able to solve specific psychological and societal problems like aggressive in nature, tendency of crime etc. The fMRI technique is mostly used in research on normal brain functioning because it has yet to be proved that consistent results could be obtained in patients with pathological conditions. However, a major research advantage to fMRI is that there is a natural correspondence to MRI structural images. This provides an anatomic basis to the functional localizations. It can also easily identify multiple regions of activation without the modeling or registration complications of other imaging techniques. Using these features we can solve the above mentioned problems. This document illustrates the basic concepts of fMRI and authors are interested to write a complete overview for the beginners.

VIII. ACKNOWLEDGMENT

Authors are thankful to Mr. Prमित Ghosh and physician Dr. Saumendu Datta for their support to understand the “functionality” of fMRI and the HOD of the Department of Computer Science & Engineering, West Bengal University of Technology, for her continuous encouragement to write a starter guideline for those who are new in medical image processing.

REFERENCES

- [1] Devlin, Hannah. "What is functional magnetic resonance imaging (fMRI)." Psych Central. Accessed on June 16 (2008): 2012.
- [2] Lazar, Nicole. The statistical analysis of functional MRI data. Springer, 2008.
- [3] Functional Magnetic Resonance Imaging (fMRI) by Robert L. Savoy, Ph.D.
- [4] Huang- Hellinger, Frank R., et al. "Simultaneous functional magnetic resonance imaging and electrophysiological recording." *Human Brain Mapping* 3.1 (1995): 13-23.
- [5] Poser, Benedikt A., and David G. Norris. "Investigating the benefits of multi-echo EPI for fMRI at 7 T." *Neuroimage* 45.4 (2009): 1162-1172.
- [6] Kundu, Prantik, et al. "Differentiating BOLD and non-BOLD signals in fMRI time series using multi-echo EPI." *Neuroimage* 60.3 (2012): 1759-1770.
- [7] Lee, M. H., C. D. Smyser, and J. S. Shimony. "Resting-State fMRI: A review of methods and clinical applications." *American Journal of Neuroradiology* (2012).
- [8] Logothetis, Nikos K. "The neural basis of the blood–oxygen–level–dependent functional magnetic resonance imaging signal." *Philosophical Transactions of the Royal Society of London. Series B: Biological Sciences* 357.1424 (2002): 1003-1037.
- [9] Brooks, Rodney A., et al. "Nuclear magnetic relaxation in blood." *Biomedical Engineering, IEEE Transactions on* 1 (1975): 12-18.
- [10] Ungerleider, Leslie G., and Robert Desimone. "Cortical connections of visual area MT in the macaque." *Journal of Comparative Neurology* 248.2 (1986): 190-222.
- [11] Ogawa, Seiji, and Tso- Ming Lee. "Magnetic resonance imaging of blood vessels at high fields: in vivo and in vitro measurements and image simulation." *Magnetic Resonance in Medicine* 16.1 (1990): 9-18.
- [12] Ogawa, Seiji, et al. "Intrinsic signal changes accompanying sensory stimulation: functional brain mapping with magnetic resonance imaging." *Proceedings of the National Academy of Sciences* 89.13 (1992): 5951-5955.
- [13] Bandettini, Peter A., et al. "Time course EPI of human brain function during task activation." *Magnetic Resonance in Medicine* 25.2 (1992): 390-397.
- [14] Rao, Steven M., et al. "Functional magnetic resonance imaging of complex human movements." *Neurology* 43.11 (1993): 2311-2311.
- [15] Ogawa, S., et al. "Functional brain mapping by blood oxygenation level-dependent contrast magnetic resonance imaging. A comparison of signal characteristics with a biophysical model." *Biophysical Journal* 64.3 (1993): 803-812.
- [16] Holodny, Andrei I., et al. "Identification of the corticospinal tracts achieved using blood-oxygen-level–dependent and diffusion functional MR imaging in patients with brain tumors." *American journal of neuroradiology* 22.1 (2001): 83-88. Schlosser, Michael J., et al. "Functional MRI studies of auditory comprehension." *Human brain mapping* 6.1 (1998): 1-13.
- [17] Smith, Charles D., et al. "Altered brain activation in cognitively intact individuals at high risk for Alzheimer’s disease." *Neurology* 53.7 (1999): 1391-1391.
- [18] Stroop, J. Ridley. "Studies of interference in serial verbal reactions." *Journal of experimental psychology* 18.6 (1935): 643.
- [19] Leung, Hoi-Chung, et al. "An event-related functional MRI study of the Stroop color word interference task." *Cerebral Cortex* 10.6 (2000): 552-560.
- [20] Stevens, Alexander A., et al. "Cortical dysfunction in schizophrenia during auditory word and tone working memory demonstrated by functional magnetic resonance imaging." *Archives of General Psychiatry* 55.12 (1998): 1097.
- [21] Posner, Michael I., and Marcus E. Raichle. *Images of mind*. Scientific American Library/Scientific American Books, 1994.
- [22] Raichle, Marcus E., and Mark A. Mintun. "Brain work and brain imaging." *Annu. Rev. Neurosci.* 29 (2006): 449-476.
- [23] Datta, Soma, and Samir Kumar Bandyopadhyay. "Segmentation of MRI Brain Images for Automatic Diagnosis."
- [24] Ahsan, Humera, Muhammad Akbar, and Atta-ul-Aleem Bhatti. "Application and advantage of functional magnetic resonance imaging and blood oxygen level dependant (BOLD) imaging modality." *Journal of the Pakistan Medical Association* 59.11 (2009): 794.
- [25] Holodny, Andrei I., et al. "Decreased BOLD functional MR activation of the motor and sensory cortices adjacent to a glioblastoma multiforme: implications for image-guided neurosurgery." *American journal of neuroradiology* 20.4 (1999): 609-612.

- [26] Holodny AI, Schulder M, Liu WC, Maldjian JA, Kalnin AJ. Decreased BOLD Functional MR Activation of the Motor and Sensory Cortices adjacent to a Glioblastoma Multiforme: Implications for Image-Guided Neurosurgery. *Am J Neuroradiol* 1999; 20: 609-12
- [27] George, Mark S., Terence A. Ketter, and Robert M. Post. "SPECT and PET imaging in mood disorders." *Journal of Clinical Psychiatry* (1993).
- [28] Turkington, Timothy G., et al. "Accuracy of registration of PET, SPECT and MR images of a brain phantom." *Journal of nuclear medicine: official publication, Society of Nuclear Medicine* 34.9 (1993): 1587-1594.
- [29] Sharon, Dahlia, et al. "The advantage of combining MEG and EEG: comparison to fMRI in focally stimulated visual cortex." *Neuroimage* 36.4 (2007): 1225-1235.
- [30] Aue, Tatjana, Leah A. Lavelle, and John T. Cacioppo. "Great expectations: What can fMRI research tell us about psychological phenomena?." *International Journal of Psychophysiology* 73.1 (2009): 10-16.
- [31] Kim, Hye Suk, et al. "Speckle reducing anisotropic diffusion based on directions of gradient." *Advanced Language Processing and Web Information Technology, 2008. ALPIT'08. International Conference on. IEEE, 2008.*
- [32] Li, Stan Z. *Markov random field modeling in computer vision*. Springer-Verlag New York, Inc., 1995.
- [33] Li, Ning, Miaomiao Liu, and Youfu Li. "Image segmentation algorithm using watershed transform and level set method." *Acoustics, Speech and Signal Processing, 2007. ICASSP 2007. IEEE International Conference on. Vol. 1. IEEE, 2007.*
- [34] Likar, Bostjan, Max A. Viergever, and Franjo Pernus. "Retrospective correction of MR intensity inhomogeneity by information minimization." *Medical Imaging, IEEE Transactions on* 20.12 (2001): 1398-1410.
- [35] Datta, Soma, Debotosh Bhattacharjee, and Pramit Ghosh. "Path Detection of a Moving Object." *International Journal of Recent Trends in Engineering* 2.3 (2009).
- [36] Ghosh, Pramit, et al. "Automatic White Blood Cell Measuring Aid for Medical Diagnosis." *Process Automation, Control and Computing (PACC), 2011 International Conference on. IEEE, 2011.*
- [37] Ghosh, Pramit, et al. "Medical Aid for Automatic Detection of Malaria." *Computer Information Systems—Analysis and Technologies. Springer Berlin Heidelberg, 2011. 170-178.*
- [38] Hou, Zujun. "A review on MR image intensity inhomogeneity correction." *International Journal of Biomedical Imaging* 2006 (2006).
- [39] Friston, Karl J. "Bayesian estimation of dynamical systems: an application to fMRI." *NeuroImage* 16.2 (2002): 513-530.
- [40] O'DOHERTY, JOHN P., Alan Hampton, and Hackjin Kim. "Model- Based fMRI and Its Application to Reward Learning and Decision Making." *Annals of the New York Academy of Sciences* 1104.1 (2007): 35-53.
- [41] Kim, Dae-Shik, Timothy Q. Duong, and Seong-Gi Kim. "High-resolution mapping of iso-orientation columns by fMRI." *Nature neuroscience* 3.2 (2000): 164-169.
- [42] Licht, J. D., et al. "Interactions between electrical activity and cortical microcirculation revealed by imaging spectroscopy: implications for functional brain mapping." *Science* 272 (1996): 551.
- [43] Zarahn, Eric. "Spatial localization and resolution of BOLD fMRI." *Current opinion in neurobiology* 11.2 (2001): 209-212.
- [44] Behzadi, Yashar, and Thomas T. Liu. "Caffeine reduces the initial dip in the visual BOLD response at 3 T." *Neuroimage* 32.1 (2006): 9-15.
- [45] Liau, Joy, Joanna E. Perthen, and Thomas T. Liu. "Caffeine reduces the activation extent and contrast-to-noise ratio of the functional cerebral blood flow response but not the BOLD response." *Neuroimage* 42.1 (2008): 296-305.